

行政院及所屬各機關出國報告
(出國類別：進 修)

植入式助聽器與聽神經瘤手術的最新發展

出國人姓名：廖文輝
服務機關：台北榮民總醫院
職稱：主治醫師

出國地區：美國
出國日期：91 3 15 - 91 4 22
報告日期：91 年 6 月 3 日

J3/
CO9101118

系統識別號 C09101118

公 務 出 國 報 告 提 要

頁數 18 含附件 是

報告名稱

植入式助聽器與聽神經瘤手術的最新發展

主辦機關

行政院輔導會臺北榮民總醫院

聯絡人/電話

/

出國人員

廖文輝 行政院輔導會臺北榮民總醫院 耳鼻喉部 主治醫師

出國類別 研究 實習

出國地區 美國

出國期間 民國 91 年 03 月 15 日 -民國 91 年 04 月 22 日

報告日期 民國 91 年 06 月 03 日

分類號/目 J3/醫療 J3/醫療

關鍵詞 植入式助聽器與聽神經瘤手術的最新發展

內容摘要 一考察豪斯耳科研究中心的研究及臨床教學，臨床手術情形。二加強本部耳科的顱骨研磨的教學及研究。三對於聽神經瘤手術，經內耳逆路手方式的加強及精進學習，中顱腔手術方式的學習。四對於植入式助聽器的發展情形及人工電子耳植入手術的再研討及精進。五暈眩的手術情形，造福部份病患因內科治療無效的另一種考量情形。六耳鳴的各種治療方法及其優缺點及成效情形。

本文電子檔已上傳至出國報告資訊網

出國進修 報告書

題目：植入式助聽器與聽神經手術的最新發展

耳鼻喉部 主治醫師 廖文輝醫師

地點：美國 加州豪斯耳科研究中心

時間：91年3月15日至91年4月22日

為期五周的短期進修

報告日期：91年6月3日

口頭報告日期：91年5月22日 於耳鼻喉部會議室

目的：了解目前植入式助聽器與聽神經瘤手術的最新發展情形，借以提昇個人及耳科手術的技巧。

過程：職因為耳科手術發展的需要，派往美國加州洛杉磯的豪斯耳科研究中心。(House Ear Institute)，此研究中心以聽神經瘤手術及耳科各種研究，聞名於世，職利用公假二週及個人的年休假，合計二個月進修時間，事先取得豪斯耳科研究中心的客座臨床醫師再進修計劃的資格，開始先考察此研究中心的臨床及基礎研究和教學情形。接著實際參與看診病患，住院訪視、查

房等，更幸運的是允許進入手術室，直接觀察其手術進行的情形，同時也能陪同指導教授，追蹤其病患術後門診照顧情形。同樣地，每週也有固定時間，醫師們一起研讀及討論期刊和論文，特殊病例檢討與討論等，如此能讓我個人充分了解到西方的國家的病患及其醫病關係的不同。更幸運的事，可以盡情地使用其一流的視聽圖書館。內有數十年來各式各樣手術方法及演進情形。更能真正體會到手術也是一種藝術的境界。自己利用其教學手術錄影帶，反覆地研習，同時配合實際手術室內的手術技巧，再利用其豐富的各類手術參考書及齊全的醫學期刊，能如此結合在一起輕鬆地研習，真是外科醫生的另一種高級享受。

由於事先評估其聽神經瘤病患，每週約有 2-3 例，可能需要至少二個月時間，才能看完 30 個病例，但令人訝異的事，此研究中心，每週約有 6-8 例病例，所以至第五週時已看完約 45 例聽神經瘤病患手術的情形，遂提早打道回府！

心得：此次短期進修原本是專注於一些臨床手術技巧的學習

及精進，幸運地卻有許多意想不到的其他收穫，分述以下各點：

- (1)充分了解到世界級的耳科研究中心的臨床教學及實際手術情形，果然令人耳目一新！
- (2)利用其圖書館的珍貴圖譜，及教學錄影帶，配合實際手術情形的印証，如此加強了許多顱骨研磨的技巧及以往忽略的地方。
- (3)對於聽神經瘤經內耳迷路的手術方式，更為清楚及深刻，同時也學習到其令人觀止的經中顱腔手術方式的精湛技巧。
- (4)認識到目前植入式助聽器的最新發展情形，同時也了解到各種人工電子耳(Nucleus. Medel Clarion)的優缺點及特色，並且學習到植入人工電子耳手術的一些特別技巧及應該注意事項。
- (5)對於一些暈眩病患，當內科治療無效時，可以考量外科手術治療的方法。
- (6)因參加其耳鳴治療的研討會，學習到一些新的觀念及治療方式，期能對於治療耳鳴病患能有所突破。

建議：此次的短期進修，對於個人的受益良多，雖然自己每年至少參加 1-2 次國際會議，或短期訓練課程，以提醒自己時時能趕上時代進步。但是總感覺仍有許多地方仍無法深入和突破。畢竟走馬看花的參觀，未若腳踏實地的觀察那樣地有充實感很感上級長官們能以最快速地方案，達成我個人出國進修的目的，若依照原計劃的出國進修，須等到一年後，有時可能已失去了時效性及學習的動機，所以建議院方應多鼓勵多利用個人的年休假模式，出國做短期的進修(1-2 個月)，如此能較為有效率且能專注特定的主題，進行研習。最後，再次感謝院方給我這次開拓視野的機會！

What is the Vibrant Soundbridge? (Implantable hearing aids)

The Vibrant Soundbridge is a breakthrough in the treatment of sensorineural hearing loss. This FDA approved device produces sound that is clear and natural, lets you enjoy a completely open ear canal and significantly reduces acoustic feedback.

IT IS .

- An entirely new approach in the treatment of moderate to severe sensorineural hearing loss
- An *implantable middle ear hearing device* that has clinically demonstrated significant advantages over hearing aids

IT IS NOT

- Not an in-the-canal device
- Not based on conventional hearing aid acoustic technology
- Not a cochlear implant
- Not for conductive hearing loss

So if you wear hearing aids, we invite you to browse our website and learn how this remarkable technology can

- Significantly improve sound clarity compared to your hearing aid
- Improve your hearing in situations with disruptive background noise
- Dramatically reduce the "whistling" and feedback you experience with hearing aids
- Provide you with a more natural and comfortable fit
- Leave your ear canal completely open and unplugged

HEARING LOSS & HEARING AIDS

Approximately 28 million Americans, or about 10% of the population, have a hearing impairment. Hearing loss is one of the most prevalent chronic health conditions in the United States affecting people of all ages, in all segments of the population, and across all socioeconomic levels.

In this section, you can find out about hearing, types of hearing loss, hearing aids, and additional resources available for hearing impaired individuals

THE SOUNDBRIDGE ALTERNATIVE

The Vibrant® Soundbridge™ is not a hearing aid, it is a new category of implantable middle ear hearing devices. The Soundbridge is an implant that directly vibrates the small bones in the middle ear. It has been approved by the FDA as a safe and effective treatment option for adults with moderate to severe sensorineural hearing loss who desire an alternative to acoustic hearing aids. Prior to receiving the device, it is recommended that an individual have experience with appropriately fit hearing aids.

Extensive clinical studies conducted in the United States and Europe have documented that patients implanted with the Vibrant Soundbridge reported the following:

- Based upon subjective responses, when comparing the Vibrant Soundbridge to their own hearing aids, a majority (86% or 42/49) of patients reported significantly improved sound clarity and overall sound quality. Forty-nine (92% or 49/53) patients completed the test requirements for this study endpoint.
- The Vibrant Soundbridge significantly improved patients' perceived benefit in many listening situations, such as familiar talkers, ease of communication, reverberation, reduced cues, background noise, aversiveness of sound, and distortion of sound.
- The Vibrant Soundbridge significantly reduced acoustic feedback when compared to the patients' own hearing aids.
- Patients reported that the Vibrant Soundbridge provided better overall fit and comfort compared to their own hearing aids, and reduced maintenance issues due to cerumen and moisture accumulation.
- For most patients, the Vibrant Soundbridge did not significantly affect residual hearing, however, a small percentage (4% or 2/53) of patients experienced a decrease in residual hearing.
- The Vibrant Soundbridge provided equal or increased functional gain when compared to the patients' own hearing aid.

For most patients (96%), implantation of the Vibrant Soundbridge did not significantly affect residual hearing (unaided hearing ability), however, a small percentage (4%) of patients experienced a decrease in residual hearing.

In addition, it was documented that the Vibrant Soundbridge patients experienced equal or increased functional gain compared to their own hearing aid

Essential Prescribing Information

ARE YOU A SOUNDBRIDGE CANDIDATE?

The questions below may be helpful in determining whether you are a candidate for the Symphonix Vibrant® Soundbridge™. Successful Soundbridge users typically answer "yes" to the questions listed. If you respond with a "yes" to most of the statements you may want to discuss the Soundbridge as a potential treatment option with your hearing healthcare provider.

Keep in mind that only an Audiologist or Ear Specialist can determine whether your hearing loss is appropriate for this device. If you would like to find an Audiologist or Ear Specialist in your area that is experienced with the Vibrant Soundbridge, please click on [Locate a Center of Excellence](#).

- Do you desire clearer, more natural sounding hearing?
- Are you looking for better hearing in adverse listening environments such as background noise?
- Do you have trouble with whistling or feedback?
- Do you find it difficult to wear hearing aids because they are uncomfortable?
- Do you experience difficulty with your own voice quality due to occlusion?
- Do you experience multiple hearing aid repairs due to wax and debris build-up?

California Ear Institute at Stanford (Palo Alto, CA)
Denver Ear Associates (Denver, Colo)
Hearing Institute for Children & Adults (San Jose, Calif)
House Ear Institute (Los Angeles, Calif)
Indiana University Medical School (Indianapolis, Ind)
Lennox Hill Hospital (New York, NY)
Otologic Center, Inc (Kansas City, Mo)
Otologic Medical Center, Inc (Oklahoma City, Okla)
University of Miami School of Medicine (Miami, Fla)
University of Michigan/Ann Arbor (Ann Arbor, Mich)
Virginia Mason Medical Center (Seattle, Wash)

Papers

Luetje, C , Brackman, D , Balkany, T , Maw, J , Baker, S , Kelsall, D , Backous, D , Miyamoto, R , Parisier, S , and Arts, A. Phase III clinical results with the Vibrant Soundbridge implantable middle ear hearing device A prospective controlled multicenter study

-Otolaryngology - Head and Neck Surgery, February 2002, 126 97-107

[\(Click to view\)](#)

Snik, and Cremers First Audiometric Results with the Vibrant Soundbridge, a Semi-Implantable Device for Sensorineural Hearing Loss

-Audiology, May 1999, 38 335-338

Richards, A., Gleeson, M Clinical Review, Recent Advances, Otolaryngology

-British Medical Journal, April 1999, 319 1110-1113

Snik, Cremers, and Nijmegen Vibrant Semi-Implantable Hearing Device with Digital Sound Processing, Effective Gain and Speech Perception

-Otology & Neurotology, December 2001, 127 1433-1437

Kelsall, D Surgical Experience with the Vibrant Soundbridge

-American Journal of Otology, Accepted for Publication

Ashburn-Reed, S. The First FDA Approved Middle Ear Implant The Vibrant Soundbridge

-The Hearing Journal, August 2001 47-48

Snik, Cremers, Dillier, Fisch, Gnadeberg, Lenarz, Mazzoli, Babighian, Uziel, Cooper, Fraysse, Charachon, Sheahata-Dieler Multi-Center Audiometric Results with the Vibrant Soundbridge, a Semi-Implantable Hearing Device for Sensorineural Hearing Impairment

-Annals of Otology, Rhinology & Laryngology - Accepted for Publication

Fraysse, Lavielle, Schmerber, Enee, Truy, Vincent, Vanecloo, Sterkers Multicentric Experience and Clinical Results with the Vibrant Soundbridge

-Otology & Neurotology, April 2001, 22 952-961

Fisch, Cremers, Lenarz, Babighian, Uziel, Proops, Fitzgerald, O'Connor, Charachon, Helms, Fraysse Clinical Experience with the Vibrant Soundbridge

-Otology & Neurotology, November 2001, 22 962-972

Tjellstrom A, Luetje CM, Hough V, Arthur B, Hertzmann P, Katz B, Wallace P Acute Human Trial of the Floating Mass Transducer

-The Ear Nose and Throat Journal, April 1997, 76 204-206

Huttenbrink, K B Current Status and Critical Reflections on Implantable Hearing Aids

-American Journal of Otolaryngology, 20(4), 409-415

Gan R.Z , Ball G R , Dietz T G & Dormer K.J. Implantable Hearing Device Performance Measured by Laser Doppler Interferometry,

-The Ear, Nose, and Throat Journal, 76(5), 297-309

Ball G R., Huber, A. Scanning Laser Doppler Vibrometry of the Middle Ear Ossicles

-The Ear, Nose and Throat Journal, April 1997, 76 213-222

Snik FM, Cremers WR The Effect of the Floating Mass Transducer in the Middle Ear on Hearing Sensitivity

-American Journal of Otolaryngology, January 2000, 21 42-48

Acoustic Neuroma Overview

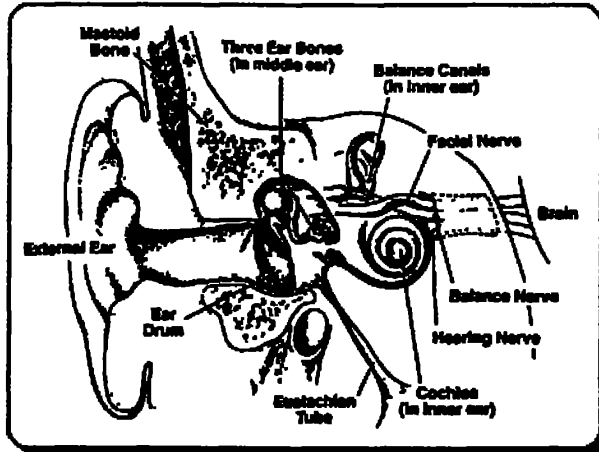


Figure A. Illustration of the anatomy of the temporal bone and inner ear structures. The vestibulocochlear nerve travels in a bony canal, the internal auditory canal, with the facial nerve. The brain stem and its vital structures are adjacent to this region.

Acoustic neuromas, also known as vestibular schwannomas, constitute approximately six percent (6%) of all brain tumors. These tumors occur in all races of people and have a very slight predilection for women over men. In the United States, approximately ten (10) people per million, per year are diagnosed with an acoustic neuroma. This translates to roughly two thousand, five hundred (2,500) newly diagnosed acoustic neuromas per year in the United States based upon a population of around two hundred and fifty million.

Acoustic neuromas are benign fibrous growths that arise from the balance nerve, also called the eighth cranial nerve or

vestibulocochlear nerve (Figure A). These tumors are non-malignant, meaning that they do not spread or metastasize to other parts of the body. The location of these tumors is deep inside the skull, adjacent to vital brain centers in the brain stem. As the tumors enlarge, they involve surrounding structures which have to do with vital functions. In the majority of cases, these tumors grow slowly over a period of years. In other cases, the growth rate is more rapid and patients develop symptoms at a faster pace. Usually, the symptoms are mild and many patients are not diagnosed until some time after their tumor has developed. Many patients also exhibit no tumor growth over a number of years when followed by yearly MRI scans.

Forms of Acoustic Neuroma

Acoustic neuromas occur in two forms: sporadic and those associated with Neurofibromatosis Type II (NF II). Approximately ninety-five percent (95%) of all acoustic neuromas are sporadic cases and are unilateral. In contrast, those tumors associated with NF II are bilateral and account for approximately five percent (5%) of acoustic neuroma patients. Patients with sporadic acoustic neuromas tend to begin having symptoms in middle age with the average being around fifty years old at diagnosis. Patients with NF II present at a younger age averaging around thirty years old when they first develop symptoms. There is a high degree of variability, however, and patients may begin having symptoms and be diagnosed with an acoustic neuroma during childhood or young adult life, as well when elderly.

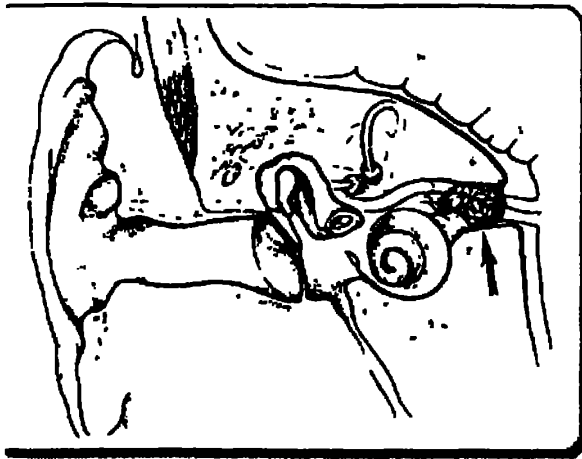


Figure B. A small acoustic neuroma (less than 1 centimeter in diameter) is typically confined the internal auditory canal

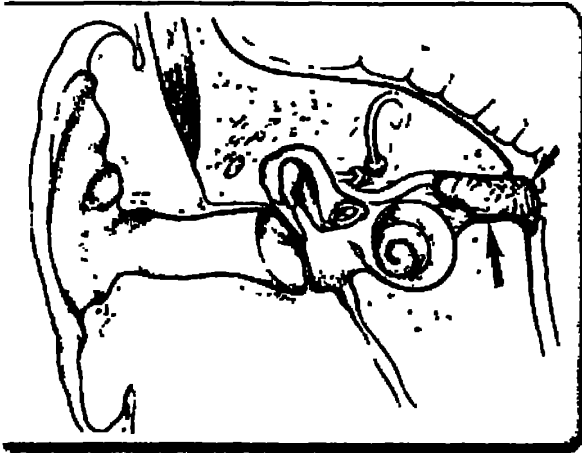


Figure C. As a tumor reaches medium size (between 1 and 3 centimeters in diameter) it extends out of the internal auditory canal and grows toward the brain stem. The larger tumors in this category make contact with the brain stem and other sensitive nerves.

NF II is a rare disease and is found in approximately one person per one hundred thousand population in the United States. In contrast, Neurofibromatosis Type I (a related, but different disease) is much more common being found in thirty to forty people per one hundred thousand population. Virtually every patient with NF II at some point manifests bilateral acoustic neuromas, while an acoustic neuroma in a patient with NF I is uncommon. Virtually no patients with NF I develop bilateral tumors as do those with NF II. Patients with NF II also have a propensity to develop benign nerve tumors in other locations which include other nerves that arise from the brain stem, as well as, nerves arising from the spinal cord and located more peripherally in the extremities. Patients with NF II, like all acoustic neuroma patients, benefit from the care of a team of experienced professionals who are capable of dealing with all aspects of their complicated case management.

The House Ear Clinic

The management of acoustic neuromas has been revolutionized by the physicians and scientists at the House Ear Clinic. In the early 1960's acoustic neuromas were treated utilizing a suboccipital approach without the aid of an operating microscope. At that time the mortality for acoustic neuroma removal in the State of California was 40%. At that time, Dr. William House, a young associate of his brother Howard, was able to diagnose a small acoustic neuroma. The patient was referred to a neurosurgeon and the neurosurgeon recommended that the tumor be observed - a common course of management at that time.

The tumor grew relatively rapidly and was then operated by the suboccipital approach without the aid of magnification. Unfortunately, this young fireman died of the surgical procedure. This had a profound effect upon Dr. William House and at that time he began doing dissections in the laboratory with the aid of magnification and subsequently developed first the middle cranial fossa and then the translabyrinthine approach for removal of acoustic neuromas.

The use of the operating microscope soon became standard practice for all approached for removal of

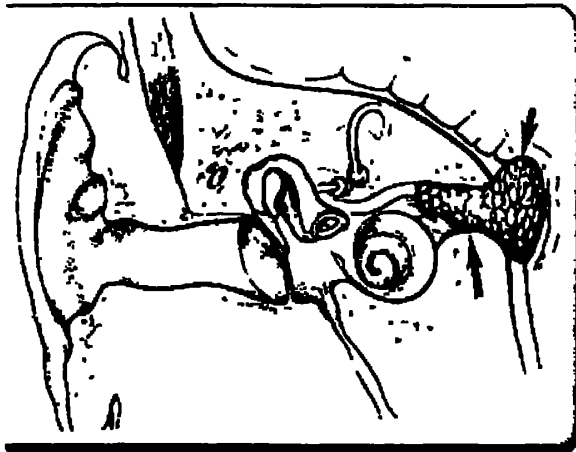


Figure D Large tumors are those which are at least 3 centimeters in diameter. These tumors press on the brain stem and cerebellum and involve other sensitive nerves which arise from the brain stem surface.

acoustic neuroma. The mortality rate rapidly fell to less than 1% and preservation of facial nerve function became the rule rather than the exception. More recently, preservation of hearing has also become a realistic goal in acoustic tumor surgery.

At the House Ear Clinic and Institute, a surgical team manages these tumors. The team consists of a neurotologist, a neurosurgeon, an internist, the anesthesiologist and then the entire support team of surgical intensive care and clinical nurses who care for the patient during their surgery and hospitalization. We believe that this team approach is important in that it adds the combined expertise of several disciplines to improve

patient outcomes.

At the House Ear Clinic all current modalities used for the treatment of acoustic neuromas are employed. In general, we favor surgical removal of the tumor but may employ stereotactic x-ray therapy when indicated. Our indication for stereotactic x-ray therapy are the same as those recommended by the consensus conference of the National Institute of Health, namely a relatively small tumor that is growing in an elderly patient or one whose medical condition is such that it is deemed inadvisable to perform surgical removal. We recommend surgery, however, for the majority of our patients.

Treatment Options

The obvious goal of therapy of any benign brain tumor is to eradicate the tumor while preserving neurologic function. There are many factors which come to bear in terms of the success of treatment for these tumors. Acoustic neuromas, because of their location in proximity to delicate brain structures and cranial nerves, are a complicated treatment problem. The treatment of these tumors is best left in the hands of professionals who have a significant and on-going experience with their treatment. An acoustic neuroma is one of a small number of brain tumors that, in order to obtain the best outcome, surgeons who frequently treat this problem must direct the patient's care. Experience in dealing with all aspects of treatment is important in order to maximize success and take advantage of all therapeutic options.

Surgical Therapy

Surgery for acoustic neuromas has been performed since the early 1900's. The initial successes were few and far between by the early pioneering neurosurgeons who treated this problem. The past

twenty years have witnessed an astounding improvement in our abilities to successfully deal with these tumors while preserving the neurological function of the patient.

Since the early 1960's, surgeons at the House Ear Clinic have been at the forefront of innovations in the surgical treatment of acoustic neuromas. Many of the most significant advances in surgical approaches to the skull base have originated from House Ear Clinic surgeons. The treatment of acoustic neuromas and other brain tumors is constantly undergoing refinement and evaluation at the House Ear Clinic. Because of this commitment to "cutting edge" and quality patient care, the House Ear Clinic has become the largest referral center for acoustic neuromas world wide. Each year, more than 200 patients with acoustic neuromas are treated by members of the House Ear Clinic team, more than at any other center in the world.

In contemporary surgical treatment of these tumors, the vast majority of patients lead a normal life following their surgery. The two main concerns that patients typically have is preservation of facial nerve function and of hearing. The facial nerve exits the brain stem and is anatomically in a position adjacent to the vestibulocochlear nerve. The anatomical relationships of the nerves to the structures of the inner ear and the brain stem can be seen in the section on anatomy. Preservation of facial nerve function is extremely important because of its cosmetic implications. Normal movement of the face on each side is controlled by the facial nerve. Any disruption leads to a loss of normal muscular tone and movement in that side of the face. Our results at the House Ear Clinic with facial nerve preservation are greater than ninety-eight percent (98%) in terms of preserving the anatomical continuity of the nerve.

Preserving anatomical continuity of the nerve means that the nerve is intact and was not disrupted by the surgical procedure. Even with an intact nerve, the functional abilities of the nerve may not be complete. However, results from our series over the years have shown excellent results in terms of functional outcome of the facial nerve. In a recently reviewed series of over three hundred and eighty (380) patients who underwent a middle fossa-type approach at the House Ear Clinic, ninety-five percent (95%) of these patients maintained excellent facial nerve function after surgery. Only five percent (5%) suffered minor weakness of the facial nerve function. Preservation of facial nerve function is dependent to some degree on the size of the tumor that is removed. The influence of tumor size on facial nerve functional outcomes is illustrated by another recent study from our group observing a recently treated group of over one hundred and ninety (190) patients via a translabyrinthine approach with tumors measuring greater than 3cm in size. In this group of patients, eighty percent (80%) had an acceptable functional outcome (House-Brackmann grades 1-3). However, only fifty-five percent (55%) of patients had an excellent outcome (House-Brackmann grades 1-2). The aforementioned series of over 380 patients all had tumors smaller than 2cm in diameter. This comparison is a good illustration of the influence of tumor size on outcome.

One of the major recent focuses of acoustic neuroma surgery is the preservation of hearing Major strides have been made in recent years in terms of improving the results of hearing preservation with surgery Much like facial nerve results, the size of tumor is an influential factor Also important is how well the patient hears prior to surgery Hearing is determined by a test called an audiogram This is performed by an audiologist If the results of the audiogram indicate that the hearing level is sufficient to indicate a reasonable chance of success with saving the hearing during surgery, then a surgical approach is selected that is designed to save hearing Otherwise, it may be advisable to choose a treatment approach that sacrifices hearing in order to obtain a total resection of the tumor

Most patients with adequate pre-operative hearing levels have small tumors which are mostly confined to the internal auditory canal In these cases, at the House Ear Clinic we routinely recommend and perform a middle fossa approach Continued refinements in this approach have led to superior hearing preservation results Some patients also are candidates for a retrosigmoid approach These are patients whom have small tumors that have only a small portion of the tumor located within the internal auditory canal However, this is a minority of patients with acoustic neuromas who have only a small component in the internal auditory canal In patients with small tumors who have been operated by the middle fossa approach at the House Ear Clinic since 1992, good hearing has been preserved in roughly two thirds of those patients Any measurable level of hearing was preserved in eighty percent (80%) of those patients

Surgical Approaches

The choice of surgical approach depends upon the size of the tumor and the level of residual hearing detected on the audiogram. Again, the larger the tumor the lower the chances of saving hearing The three most common surgical approaches for acoustic neuromas are the translabyrinthine, middle fossa and retrosigmoid approach All of these procedures are performed under general anesthesia Patients in general spend 5 days in the hospital, including the day of surgery

1 Translabyrinthine Approach

This approach was refined and popularized by surgeons at the House Ear Clinic in Los Angeles The House Ear Clinic group has the largest experience in the world with this surgical approach for acoustic neuromas and other skull base tumors The translabyrinthine approach involves an incision that is made behind the ear The mastoid bone and the balance canal structures of the inner ear are removed in order to expose the tumor This approach results in complete tumor removal in nearly every case One of the main advantages in this approach is that there is little or no retraction of the brain required to provide excellent exposure of the tumor Another advantage is early and direct localization of the facial nerve which facilitates separation of the

nerve from tumor, optimizing facial nerve outcome. After completion of tumor removal, the opening in the mastoid bone is closed with a fat graft which is taken from the abdomen.

This approach sacrifices the hearing and balance mechanism of the inner ear. As a consequence, the ear is made permanently deaf. Although the balance mechanism is removed on the operated ear, the balance mechanism in the opposite ear provides stabilization for the patient. Rarely patients experience transient vertigo immediately after surgery. This generally improves within the first five days following surgery and the patient has no further problems. In cases of larger tumors, the compensation for loss of the balance nerves on the tumor side has naturally occurred over time while the tumor has slowly grown to its large size. The patients rarely experience any vertigo in the early postoperative period.

2 Middle Fossa Approach

The middle fossa approach is another treatment that House Ear Clinic surgeons developed and currently utilize more than any other center in the world. This approach is used for small tumors and is utilized in cases when hearing is to be conserved. An incision is made beginning just in front of the ear and extends upward in a curved fashion. A small opening in the bone is made above the ear, and the membrane that covers the brain is elevated away from the bone and gently held away from the bony floor of the skull. Bone is then removed over the top of the internal auditory canal to expose the tumor. Tumor removal is complete in the vast majority of cases. Every effort is made to preserve hearing and still completely remove the tumor. In these cases of small tumors, hearing is preserved in the majority of cases in our experience at the House Ear Clinic.

3 Retrosigmoid Approach

An incision is made behind the ear and an opening in the skull is made behind the mastoid bone. The portion of the brain called the cerebellum is retracted away in order to expose the tumor. In most cases the tumor can be completely removed. Every effort is made in this approach to preserve hearing and still completely remove the acoustic neuroma. In some cases, because of invasion of the auditory nerve by the tumor, it is necessary to sacrifice hearing in order to completely remove the neuroma. The success of hearing preservation in these cases is largely dependent upon the size of the tumor and the condition of the auditory nerve in relation to the tumor.

Common Questions About Acoustic Neuromas

1 What is an acoustic neuroma? (vestibular schwannoma)

An acoustic neuroma is a benign growth which arises from the hearing and balance nerve that originates from the lower portion of the brain stem. These tumors represent approximately six percent (6%) of all brain tumors.

2 Is the tumor benign?

Yes. Acoustic neuromas are benign fibrous growths that are non-malignant, meaning that they do not spread or metastasize to other parts of the body. These tumors are, by nature, very slow growing in general. They affect adjacent nervous structures by creating pressure on these structures.

3 If I have an Acoustic Neuroma, are my children at risk for developing it, too?

The majority of acoustic neuromas are unilateral and are not hereditary. Ninety-five percent (95%) of cases are sporadic and only involve one side. This is in contrast to those tumors which are associated with a hereditary disease called Neurofibromatosis Type II (NF II). In these patients, the acoustic neuromas are bilateral. This condition is hereditary. NF II is a rare disease and it is found in approximately one person per one hundred thousand population in the United States. If someone is diagnosed with NF II, they should undergo genetic counseling.

4. Why me? What causes these tumors to develop?

The exact cause of acoustic neuromas is not currently known. There is ongoing research at the House Ear Institute and other centers to try and determine the genetic defects that occur in the tumor cells. However, no specific environmental agents have been identified which causes the development of an acoustic neuroma.

5. Does my acoustic neuroma have to be treated?

The majority of patients who present with an acoustic neuroma do have treatment of the tumor. However, these are benign, very slow growing tumors in the vast majority of cases. Therefore, it should be understood that it is rarely an emergent situation to undergo treatment once this tumor is diagnosed. Patients have time to research their options for treatment and find an experienced team to manage their care. Those who do elect to be observed and not undergo surgery or radiation therapy for the tumor, in general, do not exhibit significant changes in the tumor over time as documented by frequent MRI scans. In a recently reviewed series of one hundred and nineteen (119) mostly elderly patients followed conservatively at the House Ear Clinic over a two and a half (2 1/2) year average follow-up time, seventy

percent (70%) of the patients did not exhibit any growth of their tumor. Those that did exhibit growth or developed new symptoms went on to have surgical removal of the tumor.

6. Are there support organizations I can contact for information?

Yes. The "Acoustic Neuroma Association" is an excellent source of information. The organization provides educational material regarding acoustic neuromas and the various forms of treatment and can put you into contact with its local support group organizations.

7. What are the chances I will lose my hearing?

The chances of losing hearing prior to treatment depend upon many factors. Patients lose hearing due to these tumors from pressure effects of the tumor on the auditory nerve, as well as, invasion of the auditory nerve by the tumor. Similarly, the tumor can cause an obstruction of blood flow to the auditory nerve and the cochlea which results in hearing loss. Most patients present with hearing loss as the first symptom of their acoustic neuroma.

The chances of losing hearing completely after surgery are dependent upon the size of the tumor and the level of hearing before treatment. Patients with poor hearing before treatment have a very low chance, with any therapy, of having their hearing preserved. Patients with better hearing have a much better chance of having their hearing preserved. As noted above, in a recent series of over three hundred and eighty (380) patients with small tumors treated by the middle fossa approach here at the House Ear Clinic, roughly two thirds (2/3) of patients had their hearing preserved at a functional level. Eighty percent (80%) of patients maintained at least some measurable hearing which, in many cases, was good enough for them to use the telephone with that ear.

8. What is the chance of losing facial nerve function?

An occasional patient presents with facial nerve weakness as the first symptom of their acoustic neuroma. These patients tend to be those with larger tumors. The risk of losing facial nerve function as a consequence of surgical treatment is dependent upon the size of the tumor. Patients with small tumors have an excellent chance of having excellent facial nerve function after surgery. Patients with small tumors can expect a ninety-five (95%) chance of excellent nerve function, as judged by our recent review of patients with small tumors treated at the House Ear Clinic with a middle fossa approach. Only five percent (5%) had what is considered good facial nerve function, which translates to a grade 3 on the House/Brackmann scale. The chances of losing facial nerve function with stereotactic radiosurgery is dependent upon the dose of radiation delivered to the nerve. Preservation of good facial nerve function with radiosurgery has varied in reports in the neurosurgical literature from seventy to ninety-five percent (70-95%).

9 What is the chance the tumor will come back after treatment?

The chance of recurrence after surgical complete resection is extremely low. A study of over three thousand patients with acoustic neuromas who had their surgery at the House Ear Clinic demonstrated that the recurrence rate after total resection was 0.2% in these patients. Recurrence rates in other surgical series have, in general, been in the zero to two percent (0-2%) range after total resection. Recurrence after stereotactic radiosurgery is still undetermined at this point for patients with lower radiation doses, as are being utilized at the present time. The radiosurgical series "tumor control" rates over the short-term (i.e. approximately 2.5 years) are ninety-five percent (95%). However, it is still unknown whether "tumor control" is equivalent to what is observed after total surgical resection (i.e. less than 1% chance of tumor recurrence).

10 What type of doctor should I be consulting about my acoustic neuroma?

Ideally, a neurosurgeon or neuro-otologic surgeon who has experience with the treatment of acoustic neuromas should be consulted. Many specialized teams exist at several centers around the country who have the necessary experience and frequently treat patients with acoustic neuromas. These are difficult problems that are best handled by an experienced, multidisciplinary team in order to provide the best chance for a good outcome. It is important to find out the level of experience of the physician that is consulted. Patients should not be bashful in asking how many acoustic neuromas the doctor has treated within the past year, or in the past five to ten years, and what the results of that treatment were. Patients should expect to receive specific answers based on a review of the physician's own personal data. It is important to find out the physician's personal results with preservation of facial nerve function, hearing preservation, and the incidence of other major complications with either surgery or radiosurgery. Patients should probably be wary if a surgeon does not have easily produced statistical results (this usually means that he/she does not frequently treat these tumors). Likewise, patients should be wary of being treated by a physician who only occasionally treats this complicated problem.

11 Is this a tumor that any general neurosurgeon or otolaryngologist should be treating?

Again, the experience of the surgeon and sub-specialty training influences outcome to a tremendous degree. Patients should seek out an experienced team who frequently treats these tumors and can give sound advice based upon adequate experience.